

Nasal Angiofibroma in Elderly Woman

LORENSIA TAN

OTORHINOLARYNGOLOGY DEPT - BP BATAM HOSPITAL, INDONESIA



Background

- Angiofibroma is a rare, benign vascular tumor that usually arising in nasopharynx of adolescent males and are well-described in literature.¹⁻²
- Extra-nasopharyngeal angiofibroma is a rare lesion and controversial²⁻⁴
- A case of a 54-year-old post-menopausal woman diagnosed as nasal angiofibroma

Material and Methods

- Clinical data, sex, age, nasal endoscopy and CT Scan led to unspecific nasal mass
- Complete resection throughout endoscopic followed with histopathological

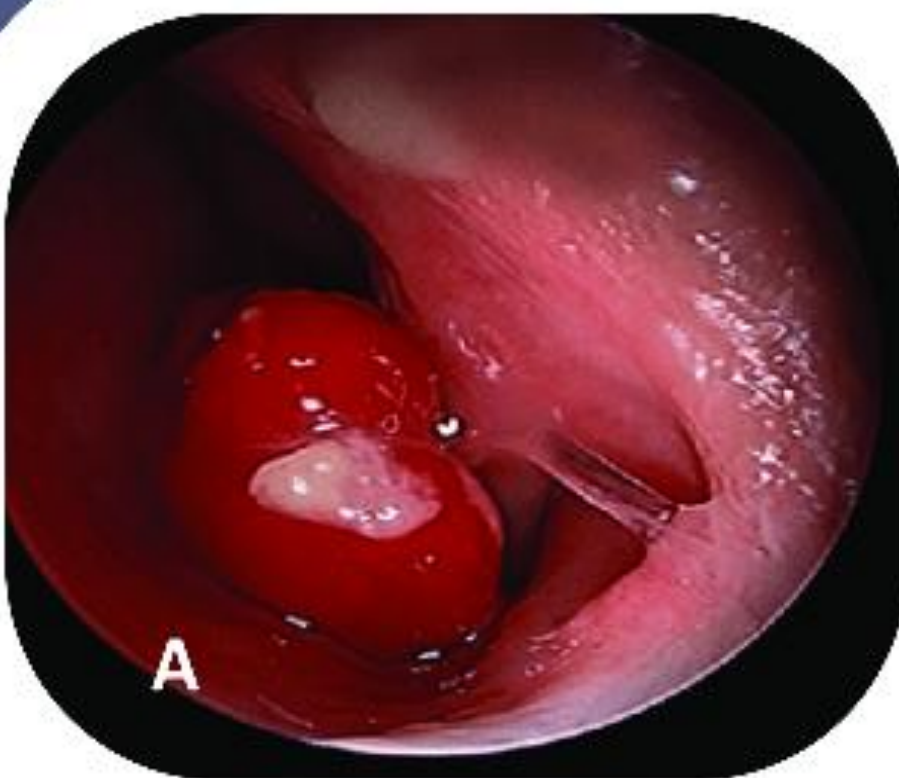

Figure A. Reddish left nasal mass ; **Figure B.** Unilateral vascular mass fullfilled nasal cavity (CT Scan)

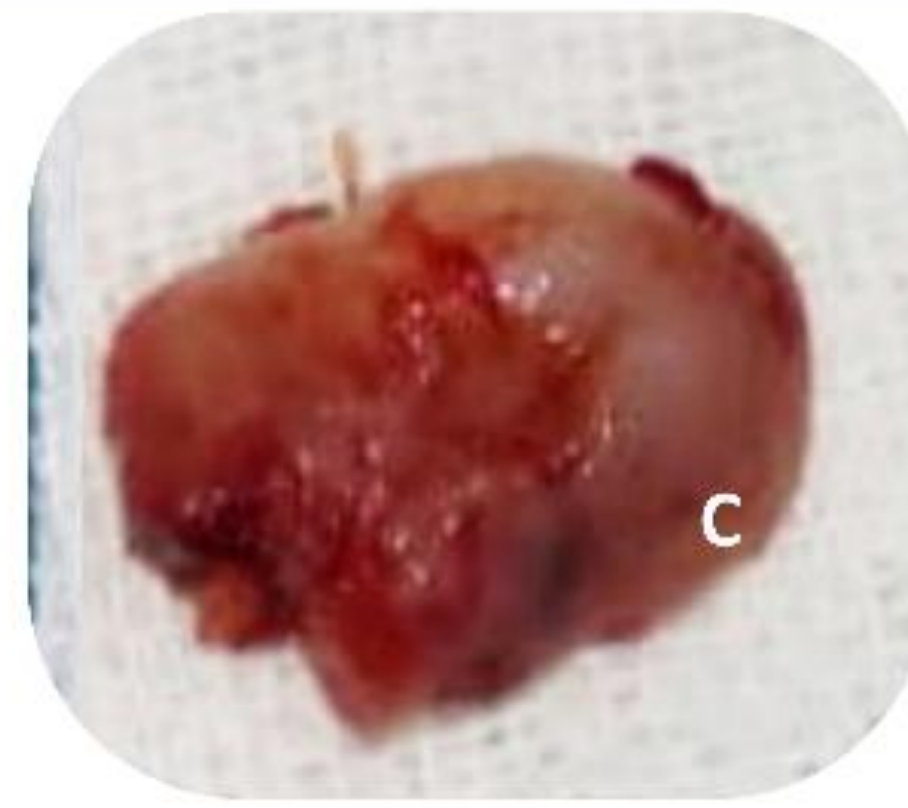
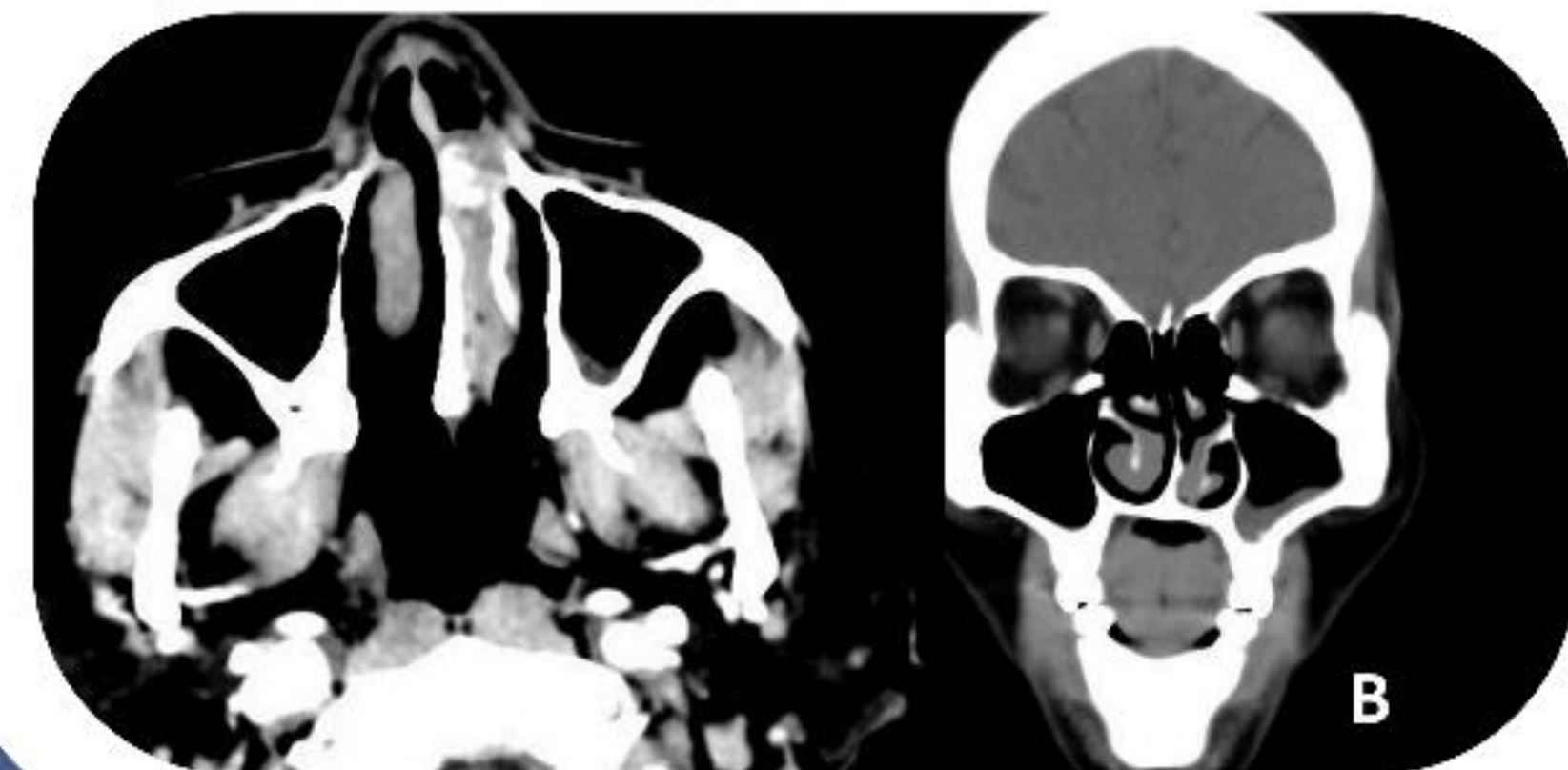


Figure C. Left nasal mass was resected

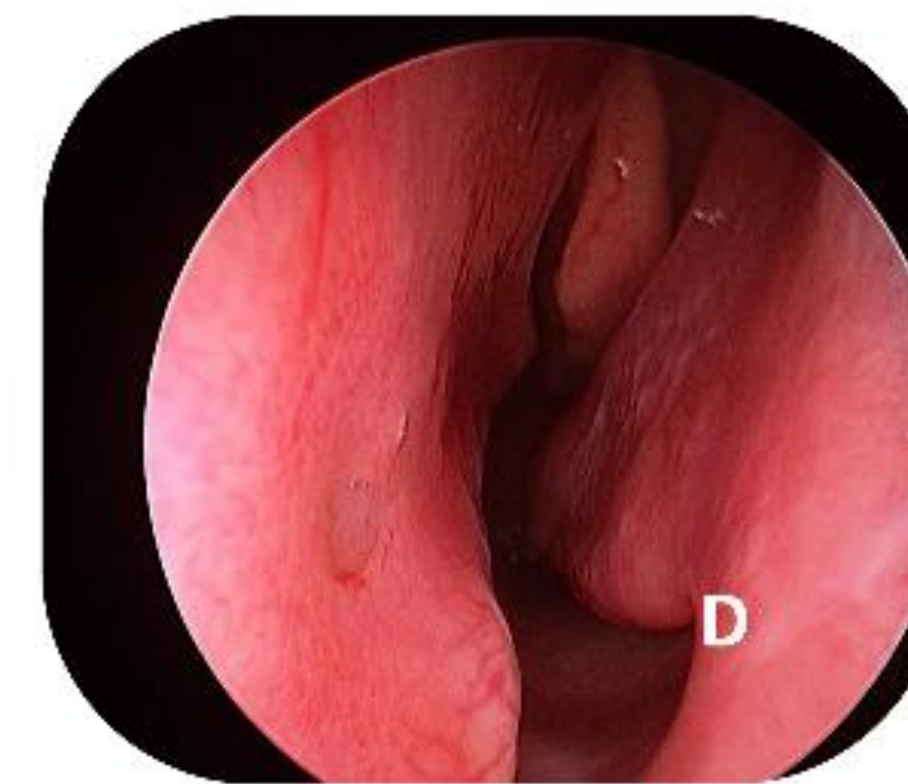


Figure D. No signs of recurrence at 8 months of follow-up

Results

- Complete surgical resection by endoscopic sino-nasal approach, revealed an Angiofibroma from histopathological. No signs of recurrence after 8 months

Conclusion

- This case is different from a classic case of angiofibroma. It occurred in atypical site and in **FEMALE** which is a **RARITY**
- Highlights that angiofibroma may be considered as differential diagnosis of nasal mass even in **elderly woman** that confirmed by histopathological finding.

References :

1. Sandie Ewe et al., Nasal Septal Angiofibroma in a Post-Menopausal Woman: A Rare Entity with Review of the Literature. Journal of Clinical and Diagnostic Research. 2015 Dec, Vol-9(12): MD03-MD05
2. Liza D K, BP K. Nasal Angiofibroma in a Female: A Rare Case Report. Glob J Oto 2017; 5(2): 555657.
3. Tang S, Luke L, Al-Shaikh S (August 10, 2023) Juvenile Nasopharyngeal Angiofibroma in Postmenopausal Females: A Potential Link With Hyperandrogenism. Cureus 15(8): e43256. DOI 10.7759/cureus.43256
4. Abdelrahman Ali et al., Nasal Angiofibroma; Ten Years' Experience of Odd Criteria. EJENTAS. 2021